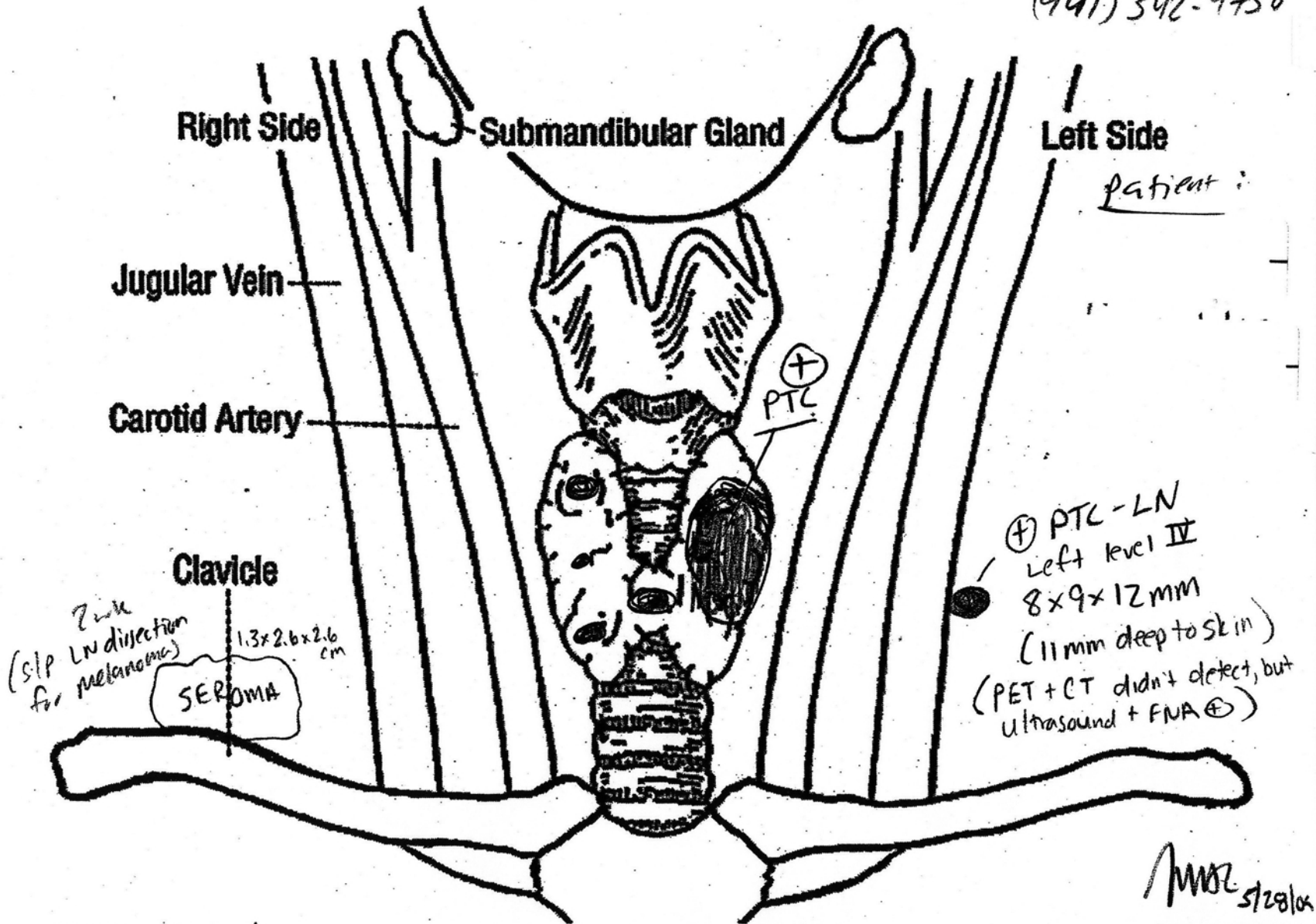


Mark Lupo, MD  
(941) 342-9750



patient:

(S/P LN dissection for melanoma)

SEROMA

1.3x2.6x2.6 cm

⊕  
PTC

⊕ PTC-LN  
left level IV  
8x9x12 mm  
(11 mm deep to skin)  
(PET + CT didn't detect, but  
ultrasound + FNA ⊕)

M. Lupo

Recommendation:

total thyroidectomy, central compartment dissection + ⊕ med neck dissection